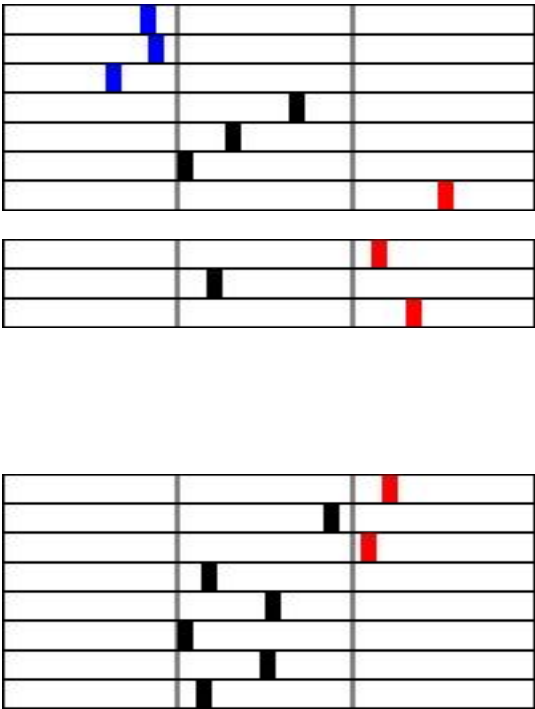


Client: DUAZO, GLACELY (112521) Gender: Male
 Patient Name: LOKI Weight:
 Species: Feline Age: 15 Months
 Breed: Siamese Doctor:

Test	Results	Reference Interval	LOW	NORMAL	HIGH
ProCyte Dx (June 1, 2023 2:38 PM)					
					5/22/23 12:23 PM
RBC	5.97 M/ μ L	6.54 - 12.20	LOW		5.22 M/ μ L
HCT	28.5 %	30.3 - 52.3	LOW		26.5 %
HGB	8.1 g/dL	9.8 - 16.2	LOW		7.1 g/dL
MCV	47.7 fL	35.9 - 53.1			50.8 fL
MCH	13.6 pg	11.8 - 17.3			13.6 pg
MCHC	28.4 g/dL	28.1 - 35.8			26.8 g/dL
RDW	31.2 %	15.0 - 27.0			27.2 %
%RETIC	1.5 %				4.7 %
RETIC	89.6 K/ μ L	3.0 - 50.0	HIGH		244.8 K/ μ L
RETIC-HGB	14.9 pg	13.2 - 20.8			19.3 pg
WBC	23.23 K/ μ L	2.87 - 17.02	HIGH		35.12 K/ μ L
%NEU	66.7 %				* 50.5 %
%LYM	26.6 %				* 37.8 %
%MONO	4.2 %				* 8.5 %
%EOS	1.9 %				3.1 %
%BASO	0.6 %				0.1 %
NEU	15.50 K/ μ L	2.30 - 10.29	HIGH		* 17.72 K/ μ L
LYM	6.18 K/ μ L	0.92 - 6.88			* 13.29 K/ μ L
MONO	0.97 K/ μ L	0.05 - 0.67	HIGH		* 2.99 K/ μ L
EOS	0.43 K/ μ L	0.17 - 1.57			1.09 K/ μ L
BASO	0.15 K/ μ L	0.01 - 0.26			0.03 K/ μ L
PLT	170 K/ μ L	151 - 600			146 K/ μ L
MPV	16.7 fL	11.4 - 21.6			19.2 fL
PCT	0.28 %	0.17 - 0.86			0.28 %



* Confirm with dot plot and/or blood film review.

1. Anemia with reticulocytosis - Likely regenerative anemia.
2. Increased RDW - Anisocytosis present - review blood film.

1. Monocytosis - Consider inflammation (if lymphopenia, consider glucocorticoid response).