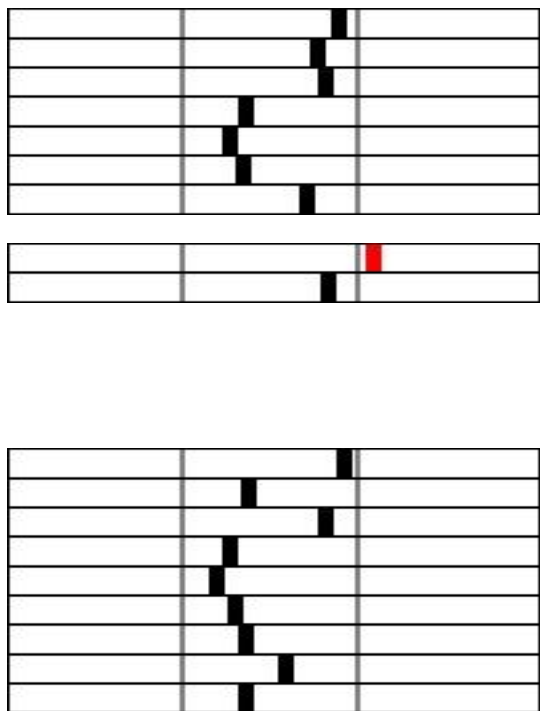


Client: FIGURA (114387)
 Patient Name: TODOROKI
 Species: Canine
 Breed: Other

Gender: Male
 Weight:
 Age: 2 Years
 Doctor: CHRISLYN JOY SANLAO

BATINGA ANIMAL MEDICAL
 CENTER

Test	Results	Reference Interval	LOW	NORMAL	HIGH
ProCyte One (February 5, 2024 5:57 PM)					
					1/22/24 11:42 AM
RBC	8.54 M/ μ L	5.65 - 8.87			8.75 M/ μ L
HCT	56.4 %	37.3 - 61.7			60.1 %
HGB	19.2 g/dL	13.1 - 20.5			20.9 g/dL
MCV	66.1 fL	61.6 - 73.5			68.7 fL
MCH	22.5 pg	21.2 - 25.9			23.9 pg
MCHC	34.1 g/dL	32.0 - 37.9			34.8 g/dL
RDW	19.4 %	13.6 - 21.7			17.9 %
%RETIC	1.6 %				0.9 %
RETIC	138.3 K/ μ L	10.0 - 110.0			75.4 K/ μ L
WBC	14.95 K/ μ L	5.05 - 16.76			11.08 K/ μ L
%NEU	73.6 %				68.8 %
%LYM	17.4 %				16.0 %
%MONO	6.4 %				11.4 %
%EOS	2.5 %				3.6 %
%BASO	0.1 %				0.1 %
NEU	11.00 K/ μ L	2.95 - 11.64			7.63 K/ μ L
LYM	2.60 K/ μ L	1.05 - 5.10			1.78 K/ μ L
MONO	0.95 K/ μ L	0.16 - 1.12			1.26 K/ μ L
EOS	0.38 K/ μ L	0.06 - 1.23			0.40 K/ μ L
BASO	0.02 K/ μ L	0.00 - 0.10			0.02 K/ μ L
PLT	251 K/ μ L	148 - 484			* 62 K/ μ L
MPV	10.4 fL	8.7 - 13.2			9.2 fL
PDW	15.3 fL	9.1 - 19.4			* 14.4 fL
PCT	0.26 %	0.14 - 0.46			* 0.06 %



↑
 PLT Aggregates Detected

* Confirm with dot plot and/or blood film review.

1. Reticulocytosis without anemia - Consider occult hemolytic or blood loss disease.