

BATINGA ANIMAL MEDICAL CENTER

Name: VELASCO,FERRERO
Animal: Dog(>15kg.)
Animal ID: 20231112-163649-A9AC
Age: 7Years
Gender: Male

CAGAYAN DE ORO CITY
Telephone: 09061211260
Fax:
Website:



Canine(>15kg) Cardiology
Exam Date: 12/11/2023
Equipment Used: Mindray Vetus 7

Clinical Indications & Data

Study Description: ECHO

Weight: 44.00kg **BSA:** 1.41m² **HR:** 76bpm

Sterilisation: Unknown

Cardiology - 1 / 3 Page

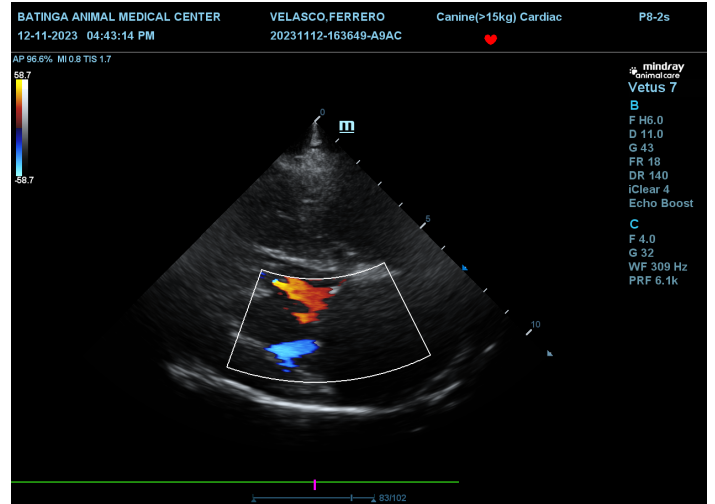
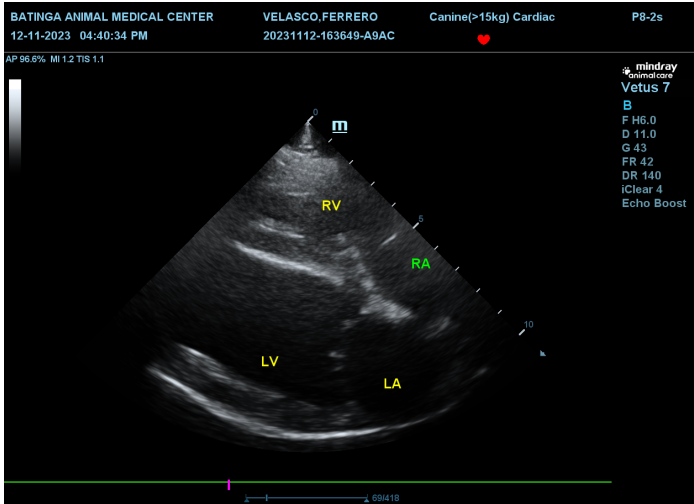
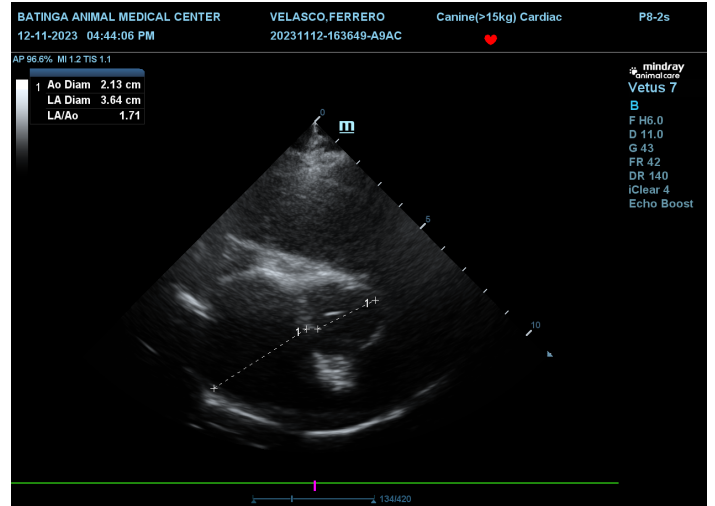
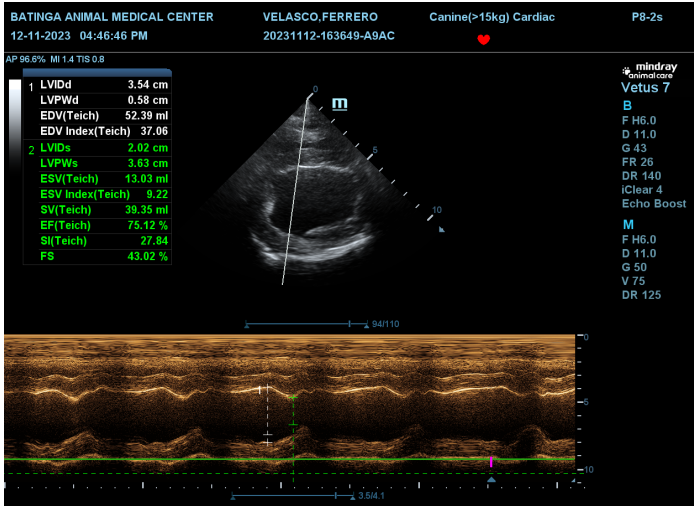
	Value	1	2	3	4	5	6	Method
<u>2D Measurements</u>								
<u>Aorta & Aortic Valve</u>								
<u>LA/Ao(2D)</u>								
LA Diam	3.64cm	3.64						Avg
Ao Diam	2.13cm	2.13						Avg
LA/Ao	1.71							
<u>M Measurements</u>								
<u>LV</u>								
LVIDd	3.54cm	3.54						Avg
LVIDs	2.02cm	2.02						Avg
LVPWd	0.58cm	0.58						Avg
LVPWs	3.63cm	3.63						Avg
FS	43.02%	43.02						
<u>Teichholz</u>								
EDV(Teich)	52.39ml	52.39						
EDV Index(Teich)	37.06	37.06						
ESV(Teich)	13.03ml	13.03						
ESV Index(Teich)	9.22	9.22						
SV(Teich)	39.35ml	39.35						
SI(Teich)	27.84	27.84						
EF(Teich)	75.12%	75.12						



Name: VELASCO,FERRERO
Animal ID: 20231112-163649-A9AC Age: 7Years Gender: Male
Canine(>15kg) Cardiology
Exam Date: 12/11/2023

Cardiology - 2 / 3 Page

Ultrasound Image





Name: VELASCO,FERRERO

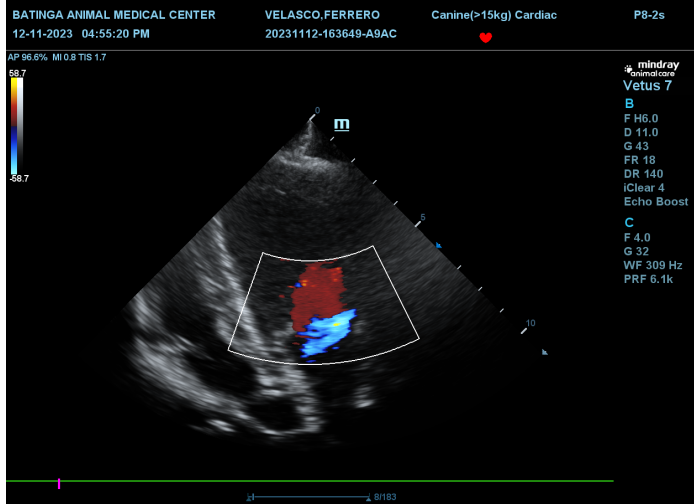
Animal ID: 20231112-163649-A9AC Age: 7Years Gender: Male

Canine(>15kg) Cardiology

Exam Date: 12/11/2023

Cardiology - 3 / 3 Page

Ultrasound Image



Comments:

1. LA/AO: 1.71
2. MV REGURGITATION
3. MV THICKENING
4. STAGE B2

Signature(seal):

Date Signed: