

BATINGA AMC Test Report of Hematology Analysis

Hospital Address:SM CITY CDO UPTOWN

Contact number:09061211260

Report No.:2606090001

Medical No.:

Test Time:2026.06.09 10:33:49

Pet Name:Sky

Pet type:Canine

Gender:Male

Age:4 Year

Sample Type:Whole blood

Owner:

Parameters	Result	Reference range	Low	Normal	High
01. WBC (White blood cell count)	18.07 10 ³ /uL↑	5.05-16.76			
NEU# (Neutrophil count)	12.64 10 ³ /uL↑	2.95-11.64			
NST# (Band neutrophil count)	0.10 10 ³ /uL	0.00-0.80			
NSG# (Segmented neutrophil count)	11.90 10 ³ /uL↑	2.50-11.30			
NSH# (Hypersegmented neutrophil count)	0.64 10 ³ /uL↑	0.00-0.40			
LYM# (Lymphocyte count)	3.86 10 ³ /uL	1.05-5.10			
SLYM# (Small lymphocyte count)	3.86 10 ³ /uL	1.05-5.10			
LLYM# (Large lymphocyte count)	0.00 10 ³ /uL	0.00-0.00			
MON# (Monocyte count)	0.98 10 ³ /uL	0.16-1.12			
EOS# (Eosinophil count)	0.59 10 ³ /uL	0.06-1.23			
BAS# (Basophil count)	0.00 10 ³ /uL	0.00-0.10			
NEU% (Neutrophil ratio)	69.94 %	52.00-78.00			
NST/WBC% (Band neutrophil ratio)	0.54 %	0.00-10.00			
NST/NEU% (Band neutrophil ratio)	0.78 %	0.00-20.00			
NSG% (Segmented neutrophil ratio)	65.84 %	50.00-75.00			
NSH/WBC% (Hypersegmented neutrophil ratio)	3.55 %	0.00-5.00			
NSH/NEU% (Hypersegmented neutrophil ratio)	5.08 %	0.00-7.00			
LYM% (Lymphocyte ratio)	21.39 %	16.00-41.50			
MON% (Monocyte ratio)	5.42 %	1.00-13.00			
EOS% (Eosinophil ratio)	3.25 %	0.50-11.85			
BAS% (Basophil ratio)	0.00 %	0.00-0.90			
02. RBC (Red blood cell count)	8.46 10 ⁶ /uL	5.65-8.87			
HGB (Hemoglobin concentration)	18.87 g/dL	13.10-20.50			
HCT (Hematocrit)	58.64 %	37.30-61.70			
MCV (Mean red cell volume)	69.28 fL	61.60-73.50			
MCH (Mean Hb per RBC)	22.29 pg	21.20-25.90			
MCHC (Mean Hb conc in RBC)	32.18 g/dL	32.00-37.90			
RDW-CV (RBC dist width-CV)	11.98 %	11.20-17.10			
RDW-SD (RBC dist width-SD)	27.17 fL	25.60-41.60			
HDW-CV (Hb dist width-CV)	16.37 %	7.00-20.00			
HDW-SD (Hb dist width-SD)	0.36 g/dL	0.20-0.80			
RET# (Reticulocyte count)	29.17 10 ³ /uL	3.00-110.00			
RET% (Reticulocyte ratio)	0.34 %	0.00-1.50			
ETG# (Shadow red cell count)	0.00 10 ¹² /L	0.00-0.05			
ETG% (Shadow red cell ratio)	0.00 %	0.00-1.65			
SPH# (Spherocyte count)	0.42 10 ⁹ /L	0.00-130.10			
SPH% (Spherocyte ratio)	0.00 %	0.00-1.54			
ACA# (Acanthocyte count)	0.42 10 ³ /uL↑	0.00-0.00			
NRBC# (Nucleated red cell count)	0.00 10 ³ /uL	0.00-0.00			
NRBC/WBC% (Nucleated red cell ratio)	0.00 %	0.00-0.00			
AGG# (Agglutinated red cell count)	0.00 10 ³ /uL	0.00-0.15			
03. PLT (Platelet count)	365.78 10 ³ /uL	148.00-484.00			
MPV (Mean platelet volume)	9.68 fL	8.70-13.20			
PDW (Platelet distribution width)	16.84 fL	9.10-19.40			
PCT (Plateletcrit)	0.35 %	0.14-0.46			
APLT# (Aggregated platelet count)	0.00 10 ³ /uL	0.00-0.15			
P-LCC (Large platelet count)	22.61 10 ³ /uL	0.00-66.00			
P-LCR (Large platelet ratio)	6.18 %	0.00-25.00			

BATINGA AMC Test Report of Hematology Analysis

Hospital Address:SM CITY CDO UPTOWN

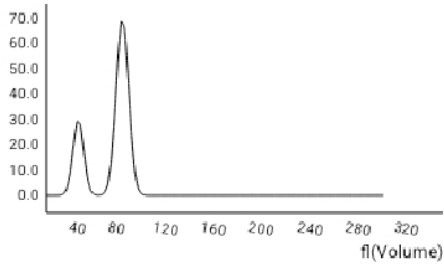
Contact number:09061211260

Report No.:2606090001

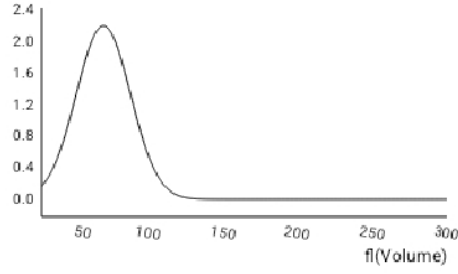
Pet Name:Sky

Pet type:Canine

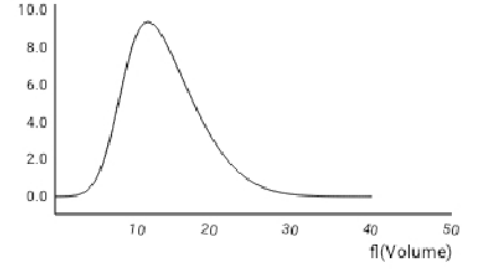
WBC



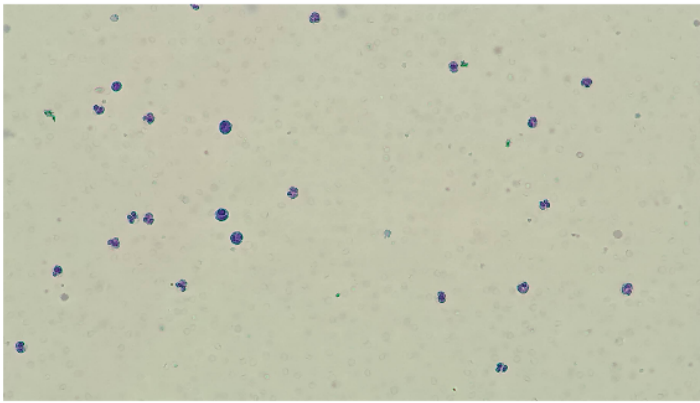
RBC



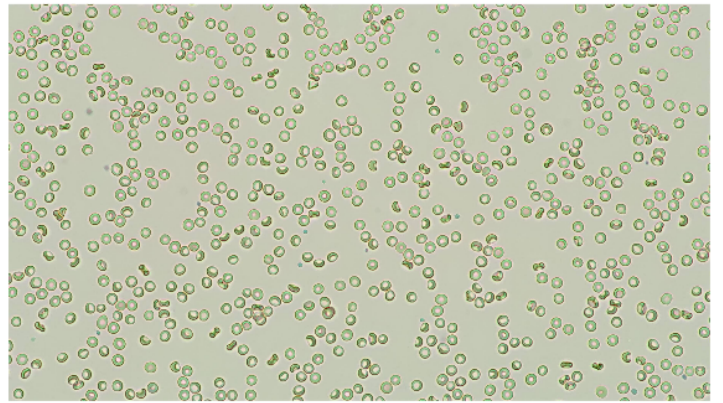
PLT



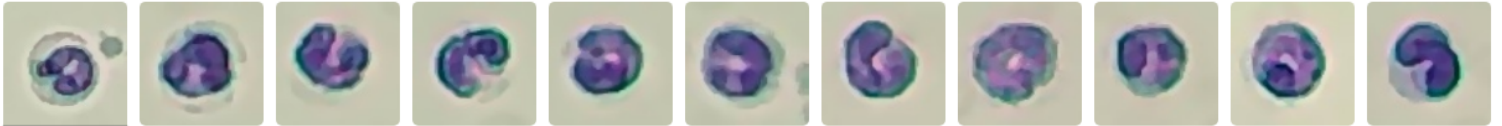
WBC images



RBC&PLT images




NST# 0.10 $10^3/uL$



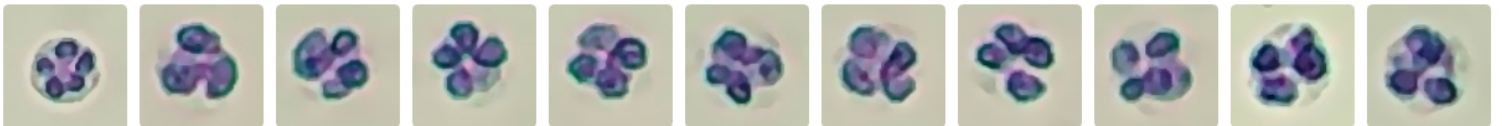STD image Number: 10 sheets/143 images/754 images

NSG# 11.90 $10^3/uL$



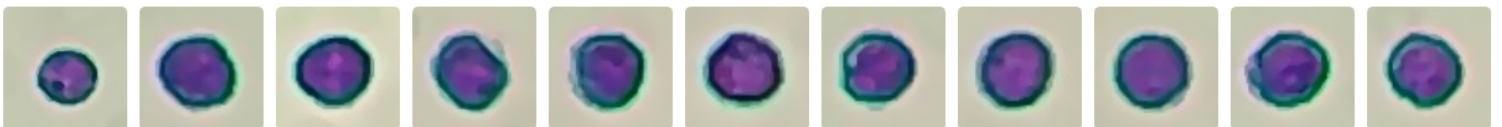
STD image Number: 1212 sheets/143 images/754 images

NSH# 0.64 $10^3/uL$



STD image Number: 64 sheets/143 images/754 images

SLYM# 3.86 $10^3/uL$



STD image Number: 400 sheets/143 images/754 images

BATINGA AMC Test Report of Hematology Analysis

Hospital Address: SM CITY CDO UPTOWN

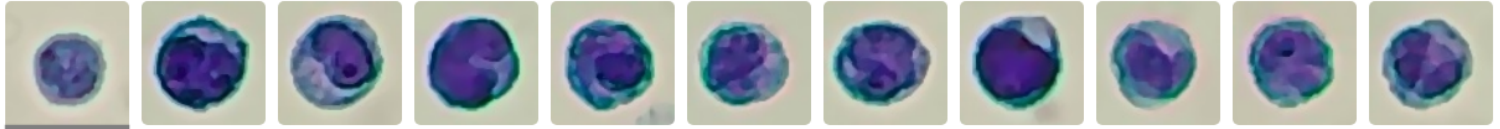
Contact number: 09061211260

Report No.: 2606090001

Pet Name: Sky

Pet type: Canine

MON# 0.98 $10^3/uL$



STD image Number: 106 sheets/143 images/754 images

EOS# 0.59 $10^3/uL$




STD image Number: 59 sheets/143 images/754 images

RET# 29.17 $10^3/uL$




STD image Number: 299 sheets/143 images/754 images

SPH# 0.42 $10^9/L$



STD image Number: 1 sheets/36 images/754 images

ACA# 0.42 $10^3/uL$



STD image Number: 1 sheets/36 images/754 images

P-LCC 22.61 $10^3/uL$



STD image Number: 1174 sheets/575 images/754 images

BATINGA AMC Test Report of Hematology Analysis

Hospital Address: SM CITY CDO UPTOWN

Contact number: 09061211260

Report No.: 2606090001

Pet Name: Sky

Pet type: Canine

1. Acute Inflammatory Response

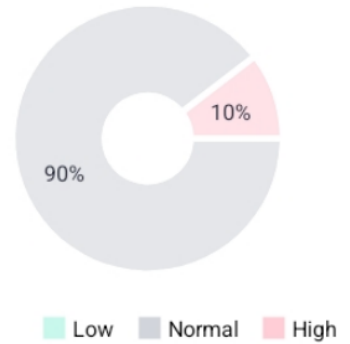
Basis for judgment: Significant elevation of neutrophils and segmented neutrophils suggests acute inflammation or bacterial infection, commonly seen in sepsis or localized suppurative infections.

2. No significant hematological abnormalities

Basis for judgment: All blood cell parameters are Within Normal Range, with no signs of anemia, infection, or inflammation, suggesting the body's blood system is basically Within Normal Range.

3. Possible changes related to organ dysfunction.

Basis for judgment: Acanthocytes are common in lipid metabolism abnormalities, often associated with liver disease or chronic illness, but have limited specificity.



WBC 18.07 $10^3/uL$ \uparrow (5.05-16.76)

-Clinical indication: Presence of acute inflammation or infection (bacterial infection is most typical), tissue injury/necrosis, drug/hormone effects, stress response, or myeloproliferative disorders.

-Basis for judgment: Bacterial infection stimulates the bone marrow to accelerate the release of White Blood Cells (WBC) to fight pathogens; inflammatory responses triggered by trauma, surgery, burns, pancreatitis, etc.; use of glucocorticoids, colony-stimulating factors, and other drugs can induce elevated WBC; physiological or pathological stress leads to redistribution of WBC, resulting in transient elevation; abnormal proliferation of hematopoietic stem cells leads to persistent and significant elevation of WBC (mostly malignant lesions).

NEU# 12.64 $10^3/uL$ \uparrow (2.95-11.64)

-Clinical indication: Suggests acute inflammation or infection (local or systemic bacterial infection), tissue necrosis, tumors, stress/cortisol effects, hemorrhage, or Hemolysis, granulocytic leukemia, etc.

-Basis for judgment: Neutrophilia is a typical manifestation of acute inflammation (surgery, trauma, infarction, tumor necrosis, thermal injury) or bacterial infection (such as pneumonia, pyelonephritis, cellulitis, pyometra); tumors can secrete granulocyte colony-stimulating factors, etc., stimulating excessive bone marrow production; Chronic Myeloid Leukemia, Myelodysplastic Syndrome (MDS), etc., where the bone marrow itself undergoes uncontrolled proliferation; exogenous corticosteroids are the most common drugs leading to iatrogenic neutrophilia.

NSG# 11.90 $10^3/uL$ \uparrow (2.50-11.30)

-Clinical indication: Commonly seen in acute bacterial infection, acute inflammation/tissue injury, stress response, or myeloproliferative lesions, drugs/hormones, poisoning, etc.

-Basis for judgment: Essentially, the bone marrow accelerates the release of mature neutrophils or the retention time of peripheral blood neutrophils is prolonged. Infectious factors (bronchitis, periodontitis, bacterial pneumonia, pyometra, bacterial enteritis, severe sepsis, bacterial peritonitis); non-infectious inflammation/tissue injury (trauma, surgery, burns, acute pancreatitis); transport fright, pain stimulation, surgical stress, history of glucocorticoid medication; Chronic Myeloid Leukemia, Polycythemia Vera, myelofibrosis (malignant, rare but high-risk).

NSH# 0.64 $10^3/uL$ \uparrow (0.00-0.40)

-Clinical indication: Right shift of neutrophil nucleus, commonly seen in Vitamin B 12 or folic acid deficiency, use of antimetabolites, long-term antibiotic or hormone use, metabolic issues, chronic inflammation, etc. Right shift is a sign of declining bone marrow hematopoietic function, often caused by severe systemic exhaustion in serious cases.

-Basis for judgment: Vitamin B 12 or folic acid deficiency affects all rapidly dividing cells, leading to DNA synthesis disorders \rightarrow delayed nuclear development resulting in a right shift. During the recovery phase of inflammation, a transient right shift of neutrophils often occurs. Severe right shift suggests bone marrow function decline; in critical illness, exhaustion of bone marrow hematopoietic function and decreased resistance indicate a poor prognosis.

ACA# 0.42 $10^3/uL$ \uparrow (0.00-0.00)

-Clinical indication: Suggests abnormal erythrocyte membrane lipids (non-specific, requires liver/kidney function correlation).

-Basis for judgment: Increased acanthocytes suggest abnormal membrane lipid composition, often related to metabolism or organ function.

Possible diseases and basis for inference

Bacterial Infection High

Multiple elevated neutrophil indicators directly point to an acute inflammatory response caused by bacterial infection.

Liver disease High

Lipid metabolism disorders affect erythrocyte membrane structure.

[1]Boden,E. Andrews,A. (2015). The Black Veterinary Dictionary (22nd Edition). London: Bloomsbury Press.

[2]Latimer,K.S. (2011). Duncan & Plath Veterinary Laboratory Medicine: Clinical Pathology (5th Edition). Ames, Iowa: Willy Blackwell Publishing House.

[3]Merck Veterinary Manual (2025). Clinical Hematology - Clinical Pathology and Operating Procedures.[4]Weiss,D.J. and Wardrop,K.J. (2010). Schalm Veterinary Hematology (6th Edition). Ames, Iowa: Willy Blackwell Publishing House.